

Intra-Cranial Tumour Boundary Delineation using a Novel MR-DTI Segmentation Technique

T L Jones, B A Bell, T R Barrick

Biomedical Imaging Group & Academic Neurosurgery Unit, St George's University of London

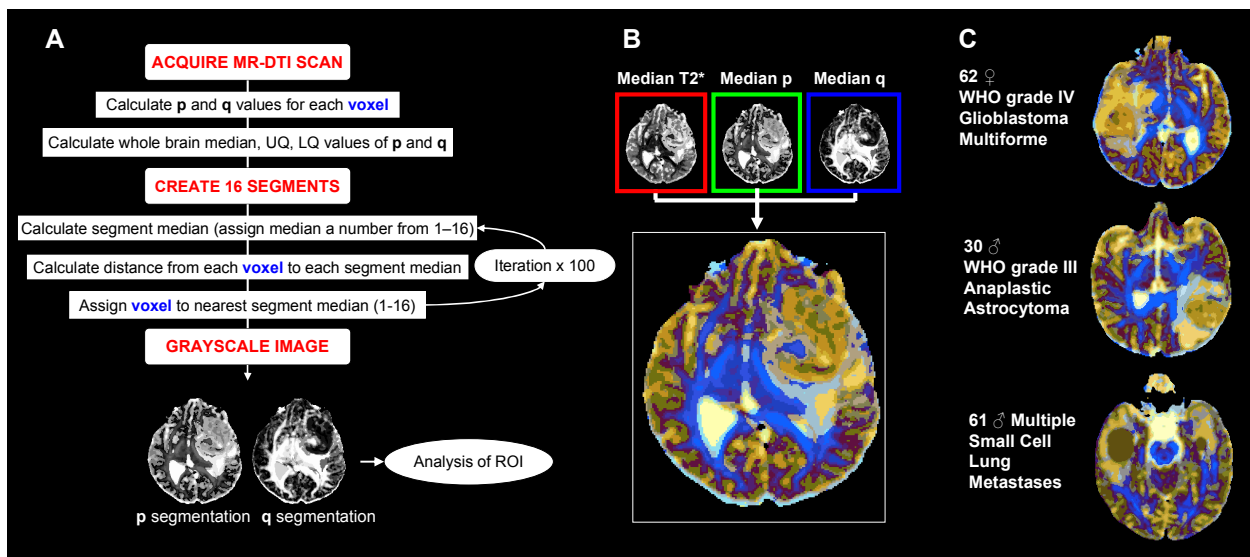
Challenge

Adult primary brain tumours have an annual incidence of 14 per 100,000. Studies suggest that standard magnetic resonance imaging (MRI) scans may underestimate local tumour infiltration and have limited ability in accurate definition of tumour boundaries. Tumour delineation is essential for effective radiotherapy planning, and optimal image guided cytoreductive surgery.

Methods

We have developed a novel diffusion tensor imaging (DTI) segmentation technique capable of delineating space occupying lesions by automatically clustering voxels with similar isotropic and anisotropic diffusion characteristics in and around the tumour.

Pre-operative diffusion tensor MR scans were acquired from 59 patients (histologically confirmed as 24 high grade glioma, 11 low grade glioma, 13 metastasis and 11 meningioma) using a 1.5T General Electric Signa MR scanner with 2.5mmx2.5mmx2.8mm resolution (TE=88ms, TR=8s). Maps of isotropic (p) and anisotropic (q) diffusion characteristics were computed [1] and then segmented using a k-medians clustering algorithm [2] which separates each voxel into one of sixteen segments based on its p and q characteristics (fig. A). RGB colour maps incorporating isotropic, anisotropic and T2*-weighted characteristics were generated to display the result of our segmentation (fig. B)



Summary of Results

Using k-medians segmentation we have delineated each identified tumour (Examples fig. C). Resulting colour images display improved visualisation of the tumour/oedema regions.

- Regions of high anisotropy (q) and low isotropy (p) (blue tones) correspond with restricted diffusion of white matter tracts.
- Regions of high isotropy (p) correspond to fluid-filled CSF spaces (yellow tones) and tumour oedema (light blue tones).
- Malignant tumours display heterogeneous diffusion.
- Within the least malignant glial tumours are dark regions which may correspond to the tumour epicentre.
- Metastases characteristically display homogenous colour throughout the tumour mass (brown regions).

Conclusion

Our application of k-medians colour segmentation creates images with clearly delineated tumour boundaries and identifies interesting foci within diffusely infiltrating lesions. This may assist in surgical biopsy target selection and define the limits for maximal tumour excision, although requires further validation.

References

1. Price SJ et al. 2006, 27:1969-74. American Journal of Neuroradiology
2. MacQueen JB, 1967. University of California Press, 1:281-297
3. Kindlmann G et al. #429 ISMRM, 16th Scientific Meeting, Toronto 2008